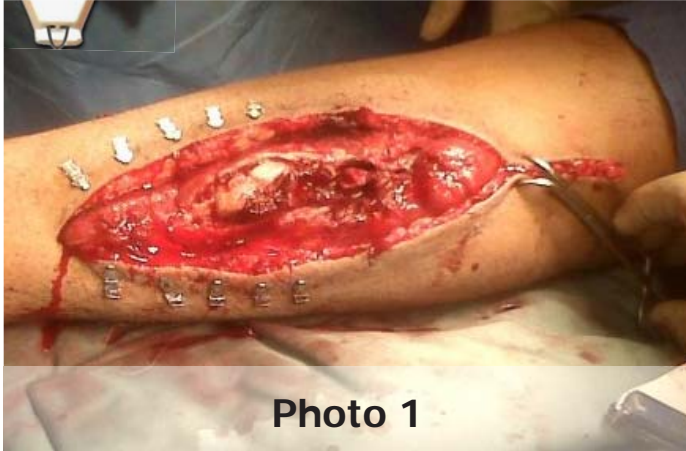
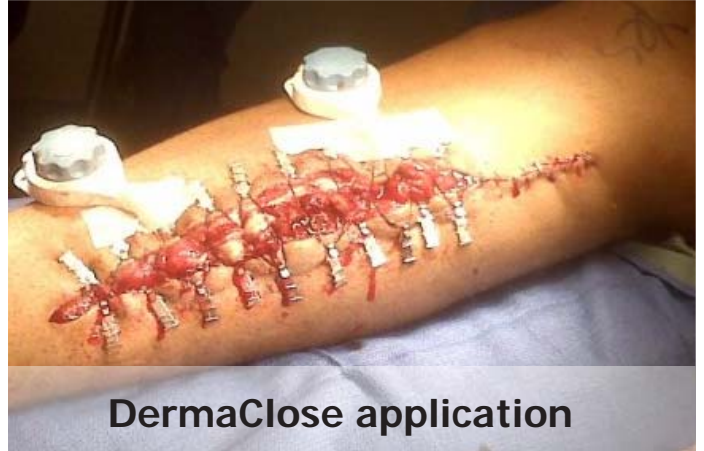


## Legs - Fasciotomy-Trauma



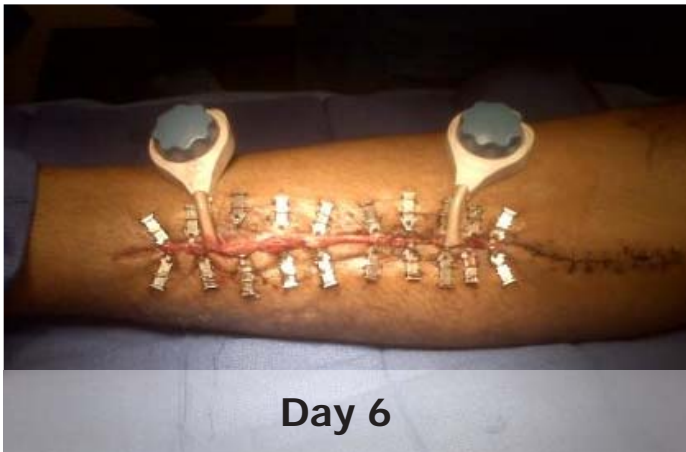
**Photo 1**

Fasciotomy wound was debrided and washed out prior to application of DermaClose RC



**DermaClose application**

Due to the size of the wound skin staples were placed proximally and two DermaClose devices were applied.



**Day 6**

On day six the wound was fully approximated enabling primary closure of the wound.

**DERMA**Close<sup>®</sup> RC  
Continuous External Tissue Expander

**WOUND**CARE<sup>™</sup>  
TECHNOLOGIES  
"Expanding Your Clinical Options"

*Expanding your clinical options*

[www.dermaclose.com](http://www.dermaclose.com) • (800)896-0436