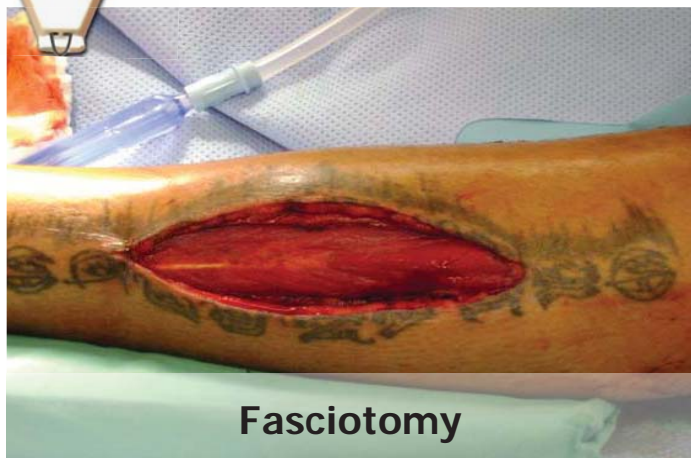

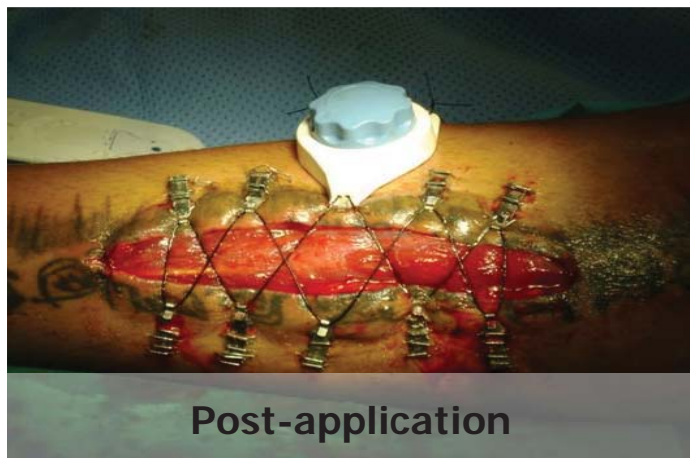


Legs - Fasciotomy - Gun Shot Wound



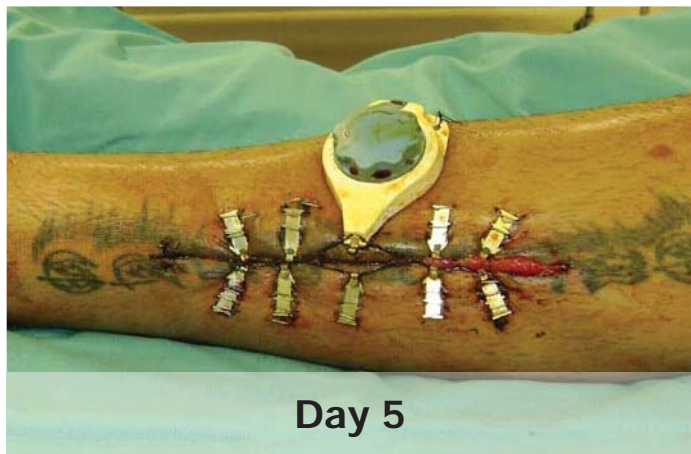Fasciotomy

This fasciotomy was performed following a gun shot wound to the lower leg. Vascular surgery repaired vessel damage and fasciotomy.



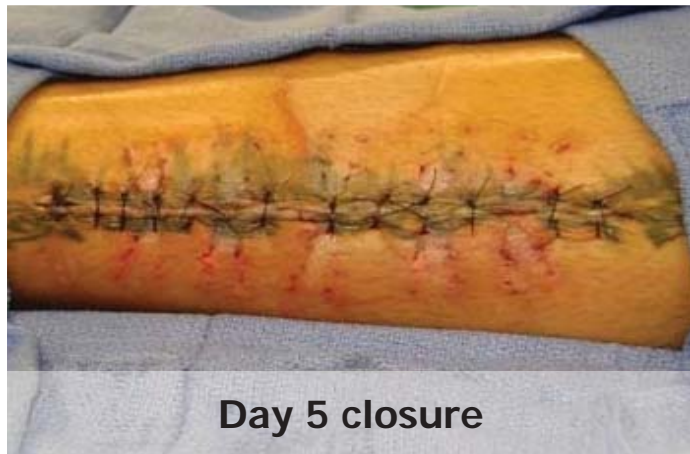Post-application

The DermaClose was placed and tightened (day 1)



Day 5

On Day 5 the margins were approximated and the wound was ready for closure.



Day 5 closure

On day 5 the wound was closed primarily with suture with tension.