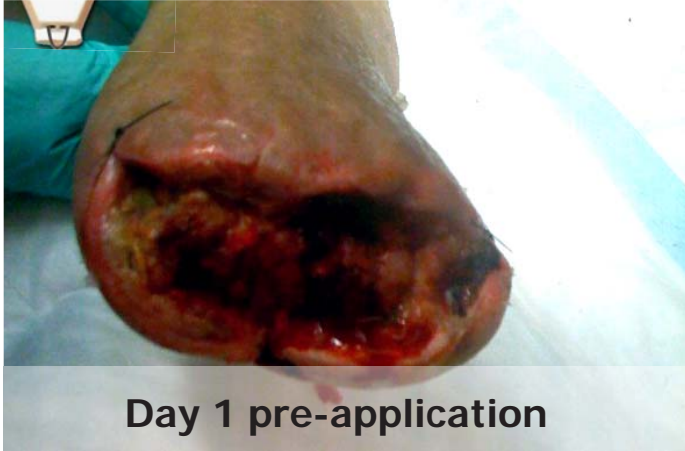
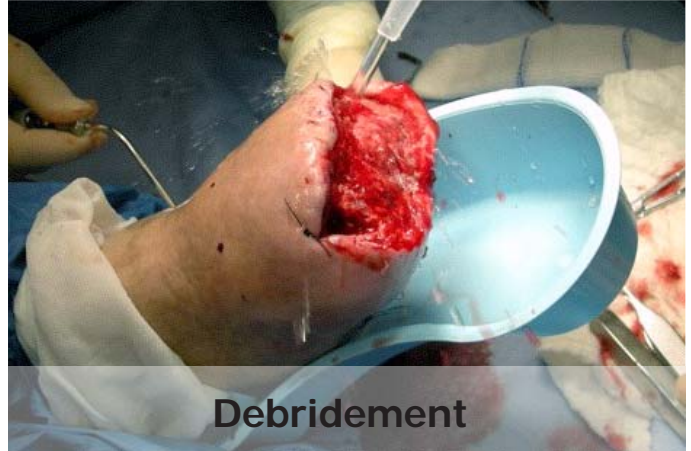


## Feet - TMA



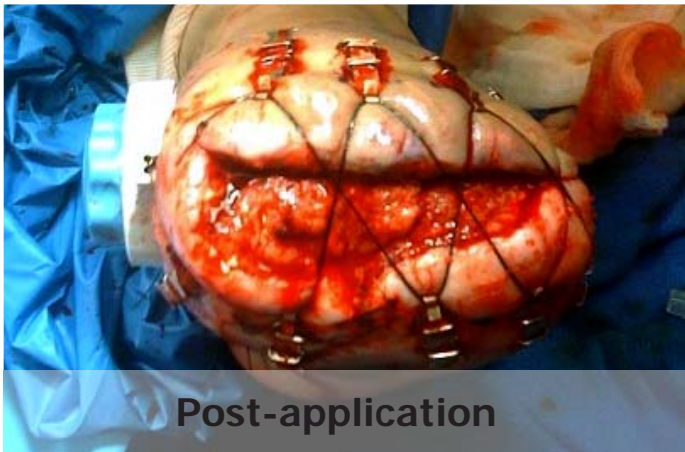
**Day 1 pre-application**

Dehisced TMA prior to debridement.



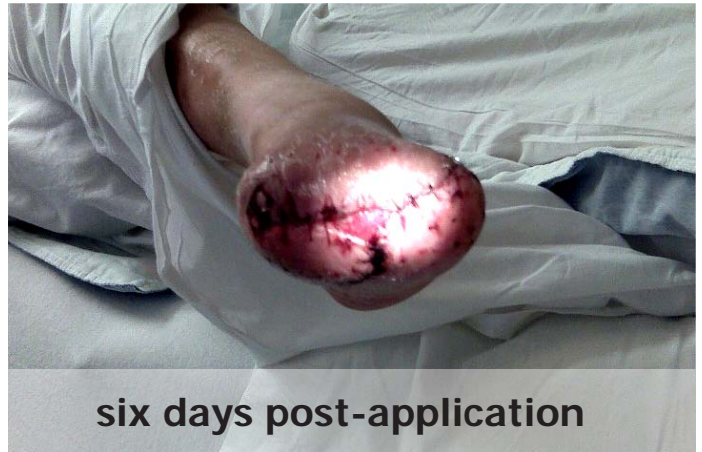**Debridement**

The wound was debrided and prepared for DermaClose application.



**Post-application**

The DermaClose was applied in a shoelace configuration. Due to concern of intact tissue damage caused by the tension line the physician decided to periodically alternate to radial application.



**six days post-application**

On day six the wound was closed by suture leaving a small area to heal by secondary intention.

**DERMA**Close<sup>®</sup> RC  
Continuous External Tissue Expander

**WOUND**CARE<sup>™</sup>  
TECHNOLOGIES  
"Expanding Your Clinical Options"

*Expanding your clinical options*

[www.dermaclose.com](http://www.dermaclose.com) • (800)896-0436