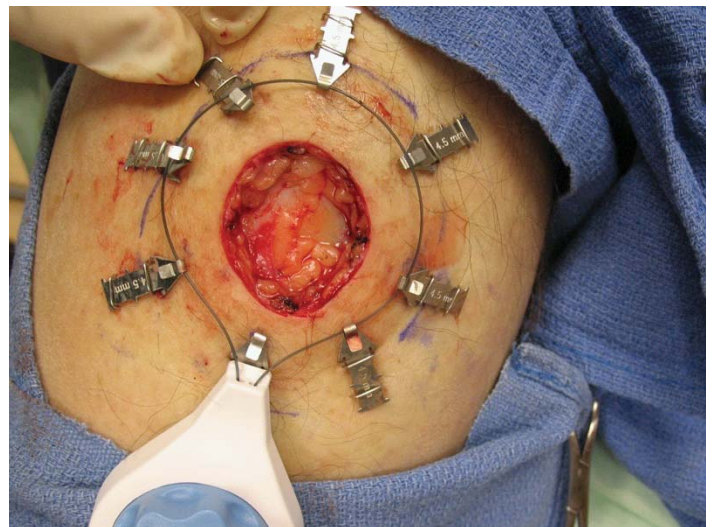
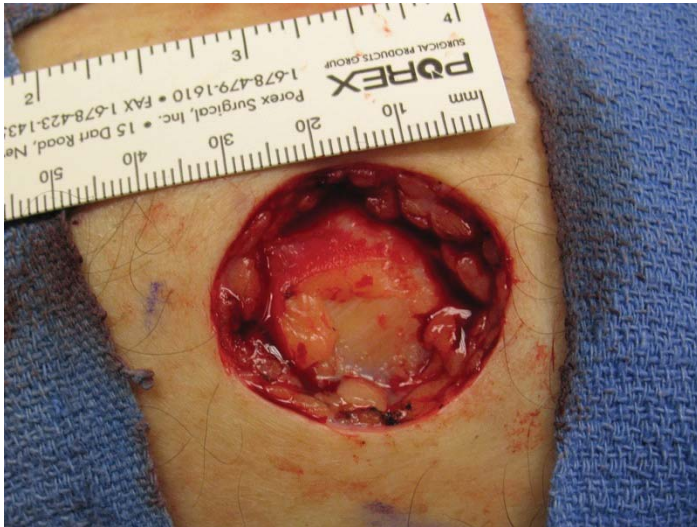

**April Farrell M.D. – Skin Care Doctors, P.A.**

**12/29/2006** – This 55-year-old male presented with melanoma of the left calf measuring 3.4 cm. Because of its size, location and morphology, Mohs surgery was indicated. The lesion was excised down to the fascia with a 1.0 cm margin along all borders. Due to its size and location we elected to use the DermaClose RC external tissue expander. The area was prepped and 1% Lidocaine with epinephrine was infiltrated.

Hemostasis was achieved with electrocautery and no undermining was performed. The skin anchors were placed and stapled into place approximately 0.5 cm from the wound edges and 2 cm apart and the tension controller was then applied. Following the winding of the tension controller the wound was approximately 60 to 70% closed.



The DermaClose device was left in place for approximately 45 minutes at which time the wound was approximately 75% closed. The patient indicated that the pain experienced was minimal and the device was then removed. Several deep pulley sutures were then placed in the subcutaneous tissue and through the dermis.

Standing cutaneous cones were removed from either end. The epidermal edges were approximated using a running 4-0 Prolene suture. The final length after closure was 6.8 cm and the procedure was performed without any complications

