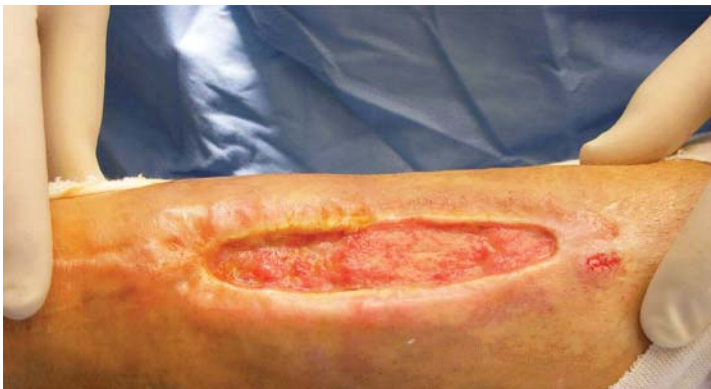

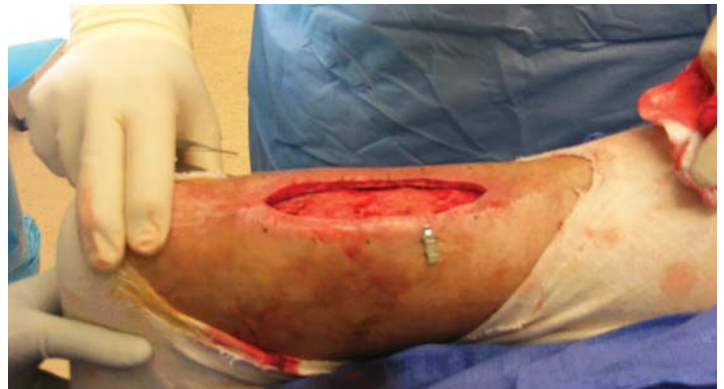**Jason R. Hanft DPM, FACFAS – Foot and Ankle Institute, South Miami, FL**

**History**

S.B is a 47 y/o male with a past medical history significant for depression and recurrent left Achilles tendon ruptures, chronic wound to the left leg 13 months duration and depression. S.B's past surgical history was significant for three open Achilles tendon surgical procedures including primary repair of an acute rupture, delayed repair of the Achilles tendon with augmentation with an allograft and a flexor hallucis tendon transfer with left hallux interphalangeal joint arthrodesis. The last Achilles tendon repair resulted in a post-operative infection and abscess requiring open incision and drainage, and intravenous antibiotics for 4 weeks. The patient experienced over 30 days of hospitalization during this course of care. His wound was further complicated by an MRSA infection requiring long term intravenous antibiotics. He later developed a wound infection with a resistant strain of pseudomonas that required 4 weeks of combination IV drug therapy. S.B's chronic wound has shown resistance to multiple treatments including sharp debridement; silver impregnated antimicrobial dressings, hydrocolloid dressings, living human skin equivalents, NPWT and immobilisation.



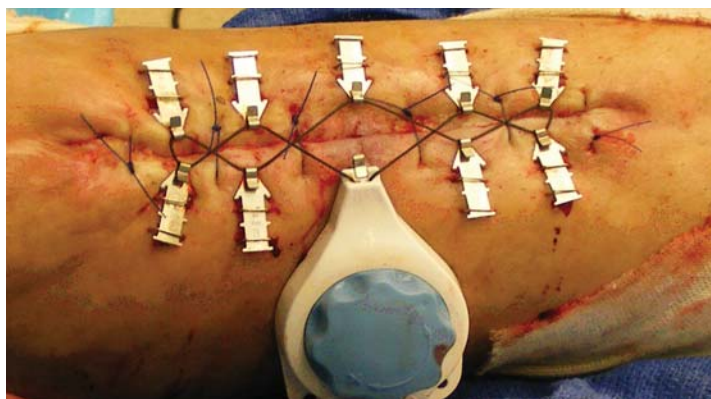
Day 1 – Wound presentation prior debridement



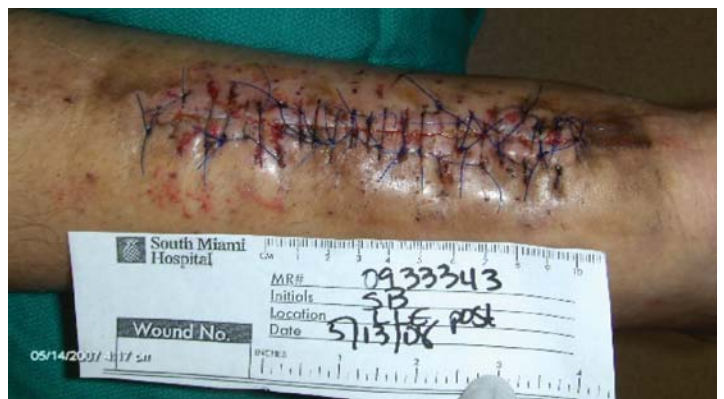Day 1 – Wound presentation post debridement and application of tissue expander

**Evaluation**

The wound was located on the posterior aspect of the left leg overlying the Achilles tendon and measured 10cm long x 3cm width (Figure1). It contained a firm fibrotic base with granular budding, elevated and slightly rolled margins, mild blanchable periwound erythema and moderate yellow serous drainage demonstrating the typical wound presentation during the past 13 months of care. Neurological examination showed mild sensory impairment surrounding the wound site. Musculoskeletal examination showed weakened plantarflexory power to the left ankle. Dorsalis pedis and posterior tibial pulses were palpable.



Day 1 – Approximation within 5 minutes of application



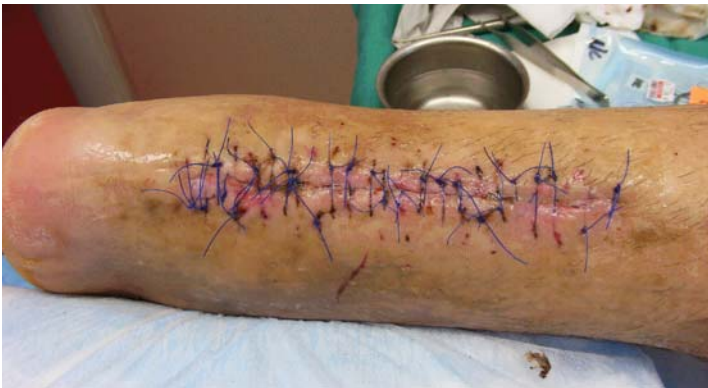Day 4 - Wound edges coapted, no post-op complications

Jason R. Hanft DPM, FACFAS – Foot and Ankle Institute, South Miami, FL

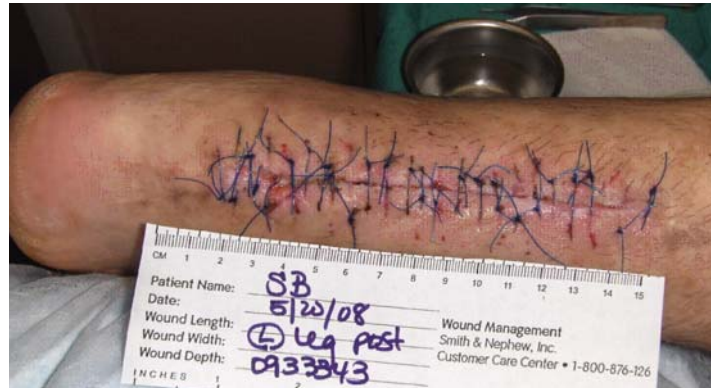**Treatment**

Preparation and Application of the DermaClose™ RC device:

S.B was brought to the operating room and sharp debridement was performed to resect 0.5 cm of the chronic wound margin. The wound bed was then debrided with a combination of hydrostatic pressure debridement with the Versa jet™ apparatus and sharp debridement with a scalpel to a healthy bleeding wound base without disrupting the underlying Achilles tendon. The surrounding wound margins were then mobilized by undermining approximately 0.5 cm. A skin-plasty was then performed at the distal and proximal wound margins in order to facilitate approximation of the distal and proximal skin edges (Figure 2). Copious irrigation was conducted utilizing 6 liters of normal saline mixed with polymyxin and Bacitracin. Two sets of deep wound cultures were taken following irrigation of the site; these were reported as no growth postoperatively. The DermaClose™ RC device was then applied to the wound site in a shoelace pattern to facilitate wound margin approximation. The skin edges were fully approximated within 5 minutes of tensioning of the DermaClose™ RC device. The device was left in place for 24 hours, the wound was inspected and the edges were coapted with out tension. The wound was further sutured closed and the device removed. The extremity was casted in a below knee gravity equines cast.



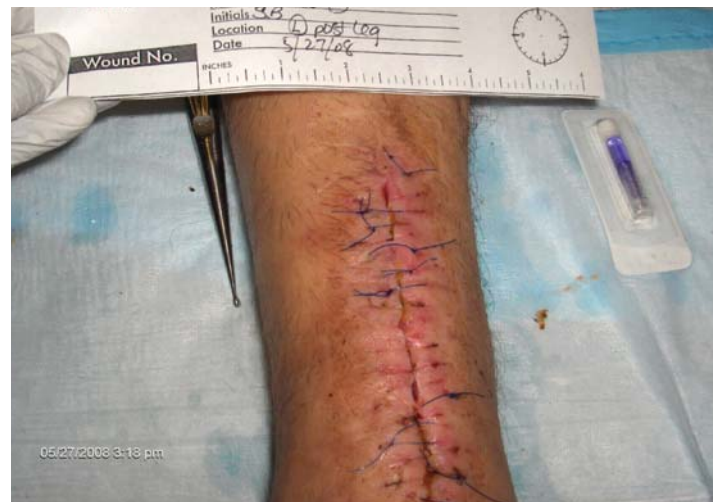Day 11 – Well approximated wound edges sutures remain



Day 18 - Wound margins healing and 50% of sutures were removed.

**Conclusion**

S.B failed to respond to aggressive local wound care modalities for over 14 months time. With application of the DermaClose™ RC device the wound was coapted within 5 minutes and sutures within 24 hours. The procedure substantially reduced the healing time and prevented further morbidity associated with chronic long standing wounds. S.B was permitted protected weight bearing in an orthopedic boot and receiving aggressive physical therapy once the wound was completely healed.



Day 25 - All sutures removed.